



## Should we be bothered with asymptomatic endocervical polyps in perimenopausal women?

Tunay Efeturk<sup>a\*</sup>, Dilek Yilmaz<sup>b</sup>, Umit Gorkem<sup>a</sup>

<sup>a</sup> Department of Obstetrics and Gynecology, Hitit University Education and Research Hospital, Corum, Turkey

<sup>b</sup> Department of Pathology, Hitit University Education and Research Hospital, Corum, Turkey

### ARTICLE INFO

### ABSTRACT

#### Article History

Received 01 / 01 / 2015

Accepted 29 / 01 / 2015

#### \* Correspondence to:

Tunay Efeturk

Department of Obstetrics and Gynecology,  
Hitit University Education and Research  
Hospital,

Corum, Turkey

e-mail: efeturktunay@yahoo.com

#### Keywords:

Asymptomatic polyps

Cervical carcinomas

Cervical polyps

Perimenopausal

Cervical polyps are defined as focal hyperplastic protrusions of endocervical folds with an incidence of 1%-10%. The majority of endocervical polyps are benign and the incidence of high-grade squamous intraepithelial lesion (HSIL) or carcinoma is relatively rare (1: 1000). Endocervical polyps are mostly incidentally discovered, however the most frequent symptoms are post-coital, post-menopausal or intermenstrual bleeding and/or profuse discharge. Here, we present a perimenopausal women with an asymptomatic polyp, later to be diagnosed with cervical carcinoma. A 46-year-old woman applied to our outpatient clinic without any complaint. The examination revealed a 2.3x2 cm cervical polyp with a slim peduncle. An immediate cervical polypectomy was performed and histopathological examination was resulted as HSIL. The patient then underwent cold-knife conization and endocervical curettage (ECC). The excized cone material's histopathology was consistent with the polyp and the cervical lesion was continuous at the surgical borders. ECC was positive for cervical intraepithelial changes. A type 1 hysterectomy was carried out. The definitive pathological diagnosis was microinvasive squamous carcinoma. Accumulating literature advises against routine polypectomy, despite the possibility of dysplasia in cervical polyps. Various clinical aspects, such as symptoms, age, menopausal status, cytological and colposcopic findings have been evaluated in conjunction with this common entity. In conclusion, the general notion that symptomatic polyps over 5 mm should be evaluated may be cost-effective, but will not discern cases of polyp associated operable microinvasive /invasive cervical carcinomas.

© 2016 OMU

### 1. Introduction

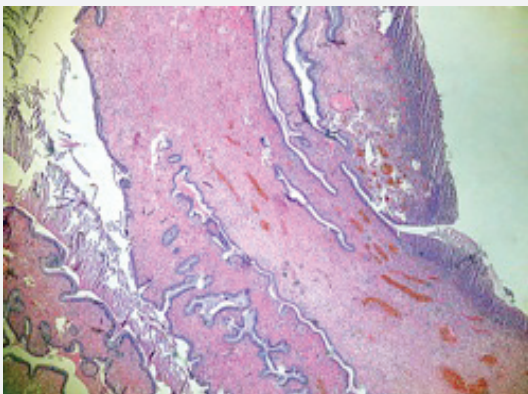
Cervical polyps, perhaps the most commonly encountered finding upon cervical examinations are defined as focal hyperplastic protrusions of endocervical folds, and seen with an incidence of 1%-10% (Farrar and Nedoss, 1961). Although they are associated with chronic inflammatory processes, exaggerated response to increased estrogen levels and local congestion of

cervical vasculature, the etiology of cervical polyps remains unclear. The majority of endocervical polyps are benign and the incidence of high-grade squamous intraepithelial lesion (HSIL) or carcinoma is relatively rare (1:1000) (Schnatz et al., 2009). Endocervical polyps are mostly incidentally discovered, however the most frequent symptoms are post-coital, postmenopausal or intermenstrual bleeding and/or profuse discharge. The

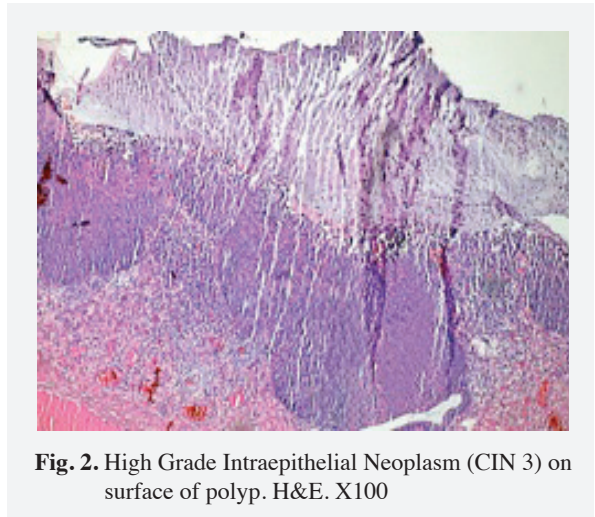
ongoing debate of routine excision of asymptomatic polyps is often supported by the fact that it is often a simple uncomplicated office procedure and it bears the chance of discovering a malignancy. Here we present a perimenopausal women with an asymptomatic polyp, later to be diagnosed with cervical carcinoma.

## 2. Case

A 46-year-old woman, gravida 2, para 2, applied to our outpatient clinic for an annual gynecological examination. Besides having occasional vaginal discharge, she had no complaints of bleeding irregularities or post-coital bleeding. She was sexually active and had been using an intrauterine device (IUD). A speculum exam revealed a 2.3x2 cm cervical polyp with a slim peduncle. A small subserous fibroid and a homogenous endometrium stripe within normal thickness range was noted on her ultrasound scan. The patient was informed of these findings and opted for immediate cervical polypectomy. The microscopic appearance of the material contained dilated endocervical glands in a mildly edematous and fibrotic stroma (Fig. 1, 2). A full-thickness section of the polyp's epithelium demonstrated extensive loss of maturation and cytological atypia, characterized by HSIL or cervical intraepithelial neoplasia 3 (CIN 3) as a prior terminology. In some places the lesion displayed involvement of the endocervical glands. The patient then underwent cold- knife conization and endocervical curettage (ECC). The excized cone material's histopathology was consistent with the polyp and the cervical lesion was continuous at the surgical borders. ECC was positive for cervical intraepithelial changes. The patient was informed regarding possible therapy strategies (including re-conization and conservative management/follow up) and chose to have a hysterectomy. Type 1 hysterectomy was carried out. The definitive pathological diagnosis was microinvasive squamous carcinoma.



**Fig. 1.** The surface of the polyp. H&E. X40



**Fig. 2.** High Grade Intraepithelial Neoplasm (CIN 3) on surface of polyp. H&E. X100

## 3. Discussion

The differential diagnosis of polypoid cervical lesions include: (Endo)cervical polyps, microglandular endocervical hyperplasia, leiomyomas, adenomyomas, fibroadenomas, squamous papillomas, condyloma accuminata, squamous cell carcinomas and adenocarcinomas. Endocervical polyps comprise the most common neoplasms of the uterine cervix. Cervical polyps are mostly benign although may be a primary site for dysplasia/malignancy (carcinoma confined to polyp) (Chin et al., 2008), an extension of a cervical malignancy and most infrequently a site of metastasis (Jimenez-Ayala et al., 1996; Omrani et al., 2004; Godfrey et al., 2010). Few studies have also reported rare gynecological malignancies mimicking benign polyps (Park et al., 2004; Jain et al., 2013). Cervical polyp showing transformation has not been demonstrated.

Whether asymptomatic polyps deserve routine removal or not, is still a matter of debate. Those in favor of this practice emphasize the possibility of overlooking malignancy. Literature regarding polypectomy frequently underline the importance of this procedure in symptomatic patients.

Accumulating literature advises against routine polypectomy, despite the possibility of dysplasia in cervical polyps. Various clinical aspects, such as symptoms, age, menopausal status, cytological and colposcopic findings have been evaluated in conjunction with this common entity. Younis et al., investigated the prevalence of pathology in 1126 cervical polyp cases and discovered two patients (0.2%) with high-grade cervical intraepithelial neoplasia, both of which were symptomatic (Younis et al., 2010). In conclusion the authors do not recommend the excision of asymptomatic polyps. Goldshmid et al. (2011), performed colposcopy on 228 women with asymptomatic cervical polyps. Abnormal colposcopy findings were detected in nine polyps, and CIN was

found in 6 of them. CIN 3 was detected in one polyp (0.4%), while none were malignant.

Berzolla et al. (2007), retrospectively evaluated 2246 cervical polyps in order to determine the prevalence of dysplasia and malignancy. The rate of malignancy and dysplasia was 0.1% and 0.5%, respectively. Only two cases of malign polyps were reported; one patient presenting with an extension of endometrial adenocarcinoma, while the other showed ovarian clear cell adenocarcinoma. The authors conclude that clinicians should bear in mind that cervical polyps can involve extracervical gynecological malignancies. Unfortunately this study did not specify the indications of polypectomy and failed to mention if the patients with dysplasia were symptomatic or not.

Aiming to discern between dysplastic and benign polyps on the basis of clinical properties, Long et al., evaluated 4328 cases, 9 of which were dysplastic (0.2%) (Long et al., 2013). Patients with dysplastic polyps were significantly younger, and tended to have polyps >20mm in diameter ( $p=0.074$ ). Although a polyp size threshold could not be established the authors concluded that younger patients were more likely to demonstrate dysplasia.

Also evaluating the impact of age and menopausal status on the prevalence of dysplasia and malignancy in cervical polyps, Schnatz et al. (2009) stated that, abnormalities within a polyp were significantly lower in postmenopausal, compared with premenopausal women. Middle-aged women (30s-50s) had a higher risk of dysplasia, however, women in the perimenopausal to postmenopausal years had a slightly higher likelihood of polyp associated malignancy (Chin et al., 2009).

These findings confirm the low rate of CIN 3 in a symptomatic cervical polyps and even lower rate of primary cervical malignancy, but do not rule out this possibility. The case disclosed herein, proves that asymptomatic cervical polyps may raise suspicion of primary cervical carcinomas. The case presented was perimenopausal and had a polyp over 20 mm in diameter, confirming the literature above. The general notion that symptomatic polyps over 5 mm should be evaluated (Casey et al., 2011) may be cost-effective but will not discern cases of polyp associated operable microinvasive/invasive cervical carcinomas, like the case presented here. More novel assessment schemes are warranted in the triage of this common entity.

## REFERENCES

- Berzolla, C.E., Schnatz, P.F., O'Sullivan, D.R., Bansal, R., Mandavilli, S., Sorosky, J.I., 2007. Dysplasia and malignancy in endocervical polyps. *J. Womens Health*. 16, 1317-1321.
- Casey, P.M., Long, M.E., Marnach, M.L., 2011. Abnormal cervical appearance: What to do, when to worry? Concise review for clinicians, *Mayo Clin. Proc.* 86, 147-151.
- Chin, N., Platt, A.B., Nuovo, G.J., 2008. Squamous intraepithelial lesions arising in benign endocervical polyps: A report of 9 cases with correlation to the Pap smears, HPV analysis, and immunoprofile. *Int. J. Gynecol. Pathol.* 27, 582-590.
- Farrar, H.K., Nedoss, R., 1961. Benign tumors of the uterine cervix. *Am. J. Obstet Gynecol.* 81, 124.
- Godfrey, G.J., Moore, G., Alattasi, H., 2010. Presentation of renal cell carcinoma as cervical polyp metastasis. *J. Low Genit. Tract. Dis.* 14, 387-389.
- Goldshmid, O., Schejter, E., Kugler, D., Menczer, J., 2011. Is removal of asymptomatic cervical polyps necessary?: Histologic findings in asymptomatic Israeli Jewish women. *J. Low Genit. Tract. Dis.* 15, 259-262.
- Jain, S., Jain, K., Chopra, P., 2013. Embryonal rhabdomyosarcoma of the uterine cervix in a 41-year-old woman: A deceptively benign entity. *Int. J. Gynecol. Pathol.* 32, 421-425.
- Jimenez-Ayala, M., Martinez-Cabruja, R., Esteban-Casado, M.L., Chinchilla Redondo, C., 1996. Serous surface papillary carcinoma of the ovary metastatic to a cervical polyp: A case report. *Acta Cytol.* 40, 765.
- Long, M.E., Dwarica, D.S., Kastner, T.M., Gallenberg, M.M., Chantigian, P.D., Marnach, M.L., Weaver, A.L., Casey, P.M., 2013. Comparison of dysplastic and benign endocervical polyps. *J. Low Genit. Tract Dis.* 17,142-146.
- Omrani, A., Schnatz, P.F., Qi, J., Greene, J., Curry, S., 2004. Lung cancer metastatic to a cervical polyp. *Gynecol. Oncol.* 92, 22.
- Park, H.M., Park, M.H., Kim, Y.J., Chun, S.H., Ahn, J.J., Kim, C.I., Sung, S.H., Han, W.S., Kim, S.C., 2004. Mullerian adenosarcoma with sarcomatous overgrowth of the cervix presenting as cervical polyp: A case report and review of the literature. *Int. J. Gynecol. Cancer.* 14, 1024-1029.
- Schnatz, P.F., Ricci, S., O'Sullivan, D.M., 2009. Cervical polyps in postmenopausal women: Is there a difference in risk? *Menopause.* 16, 524-528.
- Younis, M.T., Iram, S., Anwar, B., Ewies, A.A., 2010. Women with asymptomatic cervical polyps may not need to see a gynaecologist or have them removed: An observational retrospective study of 1126 cases. *Eur. J. Obstet. Gynecol. Reprod. Biol.* 150, 190-194.