

## Endourology

# Percutaneous Nephrolithotomy Performed on the Kidney Stone in a Patient With Ankylosing Spondylitis: A Case Study



Sercan Sari<sup>a,\*</sup>, Burhan Baylan<sup>a</sup>, Evginar Sezer<sup>b</sup>, Cem Koray Cataroglu<sup>b</sup>, Hakki Ugur Ozok<sup>a</sup>, Hamit Ersoy<sup>a,c</sup>

<sup>a</sup> Dışkapı Yıldırım Beyazıt Training and Research Hospital, Department of Urology, Ankara, Turkey

<sup>b</sup> Dışkapı Yıldırım Beyazıt Training and Research Hospital, Department of Anesthesiology and Reanimation, Ankara, Turkey

<sup>c</sup> Hitit University Faculty of Medicine, Department of Urology, Corum, Turkey

## ARTICLE INFO

## Article history:

Received 7 April 2015

Received in revised form

13 April 2015

Accepted 13 April 2015

Available online 14 May 2015

## Keywords:

Ankylosing spondylitis

Kidney

Percutaneous nephrolithotomy

Spinal deformity

Stone

## ABSTRACT

A 68-year-old man with serious cervical kyphosis and dorsolumbar scoliosis due to ankylosing spondylitis was admitted with a stone 17 mm in size in left kidney lower calyx. A percutaneous nephrolithotomy operation was decided considering the size and location of stone and the anatomical deformities of patient. The kidney was accessed through monoplaner triangulation method by giving a special position of the patient's spinal deformity and stone was successfully removed. Percutaneous nephrolithotomy is a feasible method in ankylosing spondylitis patients in case that the right position is achieved. Each patient should be assessed individually deciding on treatment methods.

© 2015 The Authors. Published by Elsevier Inc. This is an open access article under the CC BY-NC-ND license (<http://creativecommons.org/licenses/by-nc-nd/4.0/>).

## Introduction

Stone treatment in patients with spinal deformity is a serious problem for the urologists. Ankylosing spondylitis (AS) results in spinal deformities in the long-term. These spinal deformities make both conventional and minimal invasive surgical interventions difficult. This study presents a percutaneous nephrolithotomy (PNL) case which was performed by giving a special position, which has not been defined in the literature, to the spinal deformity of an AS patient with kyphoscoliosis and lower calyx stone.

## Case

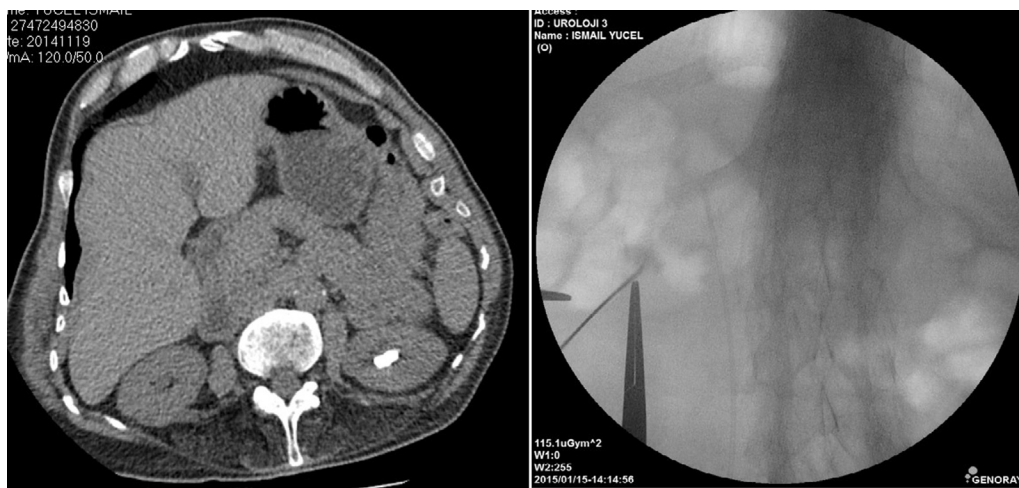
A 68-year-old male patient was admitted to our clinic due to macroscopic hematuria. Patient has never had any complaints about the stone, or undergone shock wave lithotripsy (SWL) and had an operation history. In the physical examination, it was seen that he had serious cervical kyphosis and dorsolumbar scoliosis. Also, he had advance level of movement limitation in cervical and

dorsolumbar backbone. Patient had difficult intubation criteria. The laboratory tests results were normal. Kidney ureter bladder (KUB) graph and ultrasonography (USG) visualized a stone 17 mm in size in left kidney lower calyx. Intravenous urography (IVU) of the patient was taken. It was detected with the vertebral graph and CT performed with the aim of deciding the method of treatment that the curvature in vertebral axis secondary to scoliosis was suitable for percutaneous entry into the kidney which had stone, and no retrorenal colon was visible (Fig. 1). The difficulty of the intubation and prone position was discussed with the anesthesia team and an agreement was achieved on PNL operation.

Oral intubation was performed in the patient with half-sitting position through video laryngoscope (Fig. 2). Before the procedure, 6 F ureteral catheter with two open ends was inserted in the left ureter while patient was in half sitting supine lithotomy position. Following the control with fluoroscopy, 16 F Foley catheter was inserted to the bladder and position of the patient was changed to prone. The cavity in the region starting from the head-neck until the knees of the patient was filled with silicone position pads and surgical sheets in a way which will not upset the intubation procedure and ventilation of the patient in line with the spinal deformity with the aim of achieving the prone position (Fig. 2). However, movement capability of the percutaneous entry

\* Corresponding author. Aydınliköyler Çakıldağı Sok. No. 9/5 Altındağ, Ankara, Turkey. Tel.: +90 535 6608838; fax: +90 312 3186690.

E-mail address: [sercansari92@hotmail.com](mailto:sercansari92@hotmail.com) (S. Sari).



**Figure 1.** CT image – Percutaneous entry through monoplaner triangulation method.

needle was decreased because operation table, the pads between the table and patient and the body of the patient and the mass that penetrate the C arm of fluoroscopy occupied a big area. The kidney was accessed through monoplaner triangulation method with the aim of eliminating this difficulty (Fig. 1). Dilatation was performed until 30 f with Alken metal dilators. Upon placement of renal sheath, it was entered with nephroscopy. Later on, the stone in lower calyx was fragmented with pneumatic lithotripter and the pieces were removed with forceps. At the end of the operation, stone-free status was observed with fluoroscopy. 16 F Foley catheter was inserted into the kidney for the drainage, and the procedure was finalized.

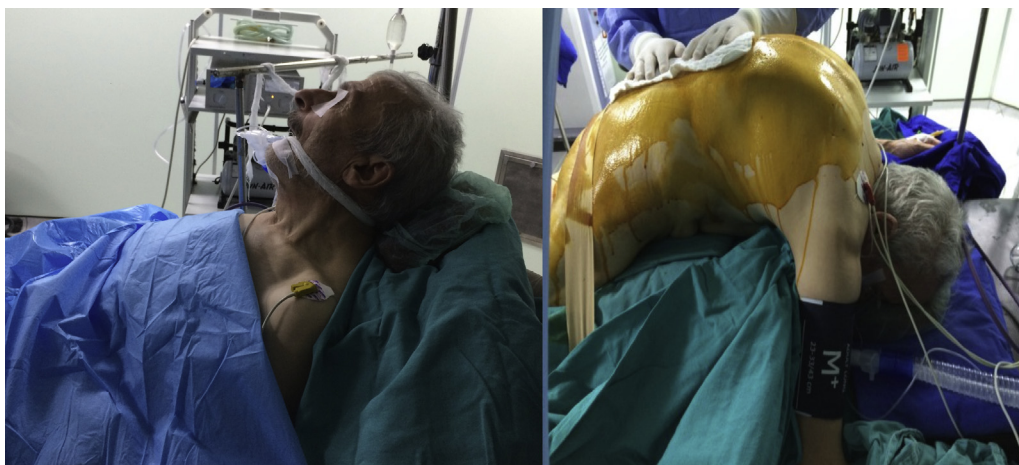No serious intraoperative bleeding was observed. Post-operative laboratory values (Total blood count, blood biochemistry) were normal. On the first postoperative day, the catheter was removed. On the third postoperative day, the drainage was removed. The patient was discharged on the fourth postoperative day.

## Discussion

AS is classified as autoimmune spondyloarthropathy disorder, which affects joints and adjacent structures including vertebra,

sacroiliac joints and hip and shoulder, and results in the fusion of spine. Genetic predisposition is involved. The fusion of vertebra leads to the appearance called as bamboo spine.<sup>1</sup> 96% of the patients express the HLA-B27 gene. The loss of flexibility of neck and vertebra poses a serious problem for these patients. It is indicated that stone disease has a higher incidence rate in AS patients.<sup>2</sup> The treatment of stone disease is an important problem. The kidney stone guideline by European Association of Urology recommends endourology (PNL or Retrograde Intrarenal Surgery – RIRS) as the first step treatment for lower pole stones 10–20 mm in size in the presence of unfavorable factors for SWL.<sup>3</sup> In our case, PNL was planned since the pelvicalyceal anatomy of the patient was not suitable for RIRS. Studies on RIRS in patients with spinal deformities are available in the literature. This study by Resorlu et al,<sup>4</sup> RIRS was performed on a kidney stone of a patient with AS. In another study percutaneous nephrolithotomy was performed to 5 patients with spina bifida.<sup>5</sup> In that study there was no image of position of operation. Our case is the first study that showed that PNL method is applicable for the patients with advanced kyphoscoliosis that develop secondary to AS.

The treatment of urinary system stone disease is getting more and more difficult in patients with spinal deformity in relation to



**Figure 2.** Intubation in half-sitting position – prone position.

intubation and the achieving the right position. No standard treatment that can be recommended is available for patients with spinal deformity. Every patient should be handled individually based on the size and location of the stone and severity of the spinal deformity. PNL is a method can be recommended in AS patients in case that intubation is successfully performed and the right position is achieved.

#### **Conflicts of interest**

All authors declare no conflicts of interest.

#### **References**

1. Jiménez-Balderas FJ, Mintz G. Ankylosing spondylitis: clinical course in women and men. *J Rheumatol.* 1993;20:2069–2072.
2. Korkmaz C, Ozcan A, Akçar N. Increased frequency of ultrasonographic findings suggestive of renal stones in patients with ankylosing spondylitis. *Clin Exp Rheumatol.* 2005;23:389–392.
3. Türk C, Knoll T, Petrik A, et al. The updated EAU guidelines on urolithiasis. *Eur Urol.* 2014;63:1169–1171.
4. Resorlu B, Ozyuvali E, Oguz U, et al. Retrograde intrarenal surgery in patients with spinal deformities. *J Endourol.* 2012;26:1131–1135.
5. Alsinnawi M, Torreggiani WC, Flynn R, et al. Percutaneous nephrolithotomy in adult patients with spina bifida, severe spinal deformity and large renal stones. *Ir J Med Sci.* 2013;182:357–361.