

Off-Pump Reduction Aortoplasty with Coronary Artery Bypass Grafting: 3 Cases



Adnan Yalçınkaya¹, Adem İlkay Diken¹, Gökhan Lafçı², Ahmet Kuddusi İrdem², Kerim Çağlı²

¹ Hitit University Faculty of Medicine, Department of Cardiovascular Surgery, Çorum, Turkey

² Türkiye High Specialization Training and Research Hospital, Clinic of Cardiovascular Surgery, Ankara, Turkey

ABSTRACT

Coronary artery disease with ascending aorta aneurysm surgery may be troublesome for both the surgeon and the patient. Because so many patients have other concomitant diseases such as cancer, severe left ventricular dysfunction, hemodialysis-dependent chronic renal failure, poor nutritional status, obesity, chronic obstructive pulmonary disease (COPD), and cerebrovascular event history. These diseases increase the risk of postoperative mortality and morbidity because of the use of extracorporeal circulation and aortic cross-clamping intraoperative. Off-pump reduction aortoplasty may be the right decision for risky patients with ascending aortic aneurysm and coronary artery disease. This report presents 3 cases of off-pump reduction aortoplasty and concomitant coronary artery bypass grafting (CABG).

Key Words: Ascending aorta; aortic aneurysm; coronary artery disease; off-pump coronary artery bypass; wrapping

Koroner Arter Baypas Greftleme ile Off-Pump Küçültücü Aortoplasti: 3 Olgu

ÖZET

Koroner arter hastalığı ile birlikte yapılan asendan aort cerrahisi hem cerrah hem de hasta için zorlu olabilmektedir. Çünkü bir kısım hastanın kanser, düşük sol ventrikül fonksiyonu, diyalize bağımlı kronik böbrek yetmezliği, kötü beslenme düzeyi, obezite, kronik obstrüktif akciğer hastalığı (KOAH) ve serebrovasküler hastalık öyküsü gibi eşlik eden diğer hastalıkları olabilir. Bu hastalıklar intraoperatif ekstrakorporeal dolaşım kullanımı ve aortun kros-klemplenmesi nedeniyle post-operatif mortalite ve morbiditeyi artırır. Off-pump küçültücü aortoplasti asendan aort anevrizması ve koroner arter hastalığının olduğu riskli hastalar için uygun karar olabilir. Bu raporda off-pump küçültücü aortoplasti ve eşzamanlı koroner arter bypass cerrahisi yapılan üç olgu sunulmuştur.

Anahtar Kelimeler: Asendan aorta; aort anevrizması; koroner arter hastalığı, off-pump koroner arter baypas; sarmak

INTRODUCTION

Ascending aorta replacement is more common than aortoplasty in case of ascending aortic aneurysm⁽¹⁾. But aortoplasty is a simple, fast, and effective method for moderately sized ascending aortic aneurysms with concomitant operations⁽²⁾. Although, both procedures need on-pump surgery, aortoplasty can be performed without extracorporeal circulation in specific situations such as cancer, severe left ventricular dysfunction, hemodialysis-dependent chronic renal failure, poor nutritional status, obesity, chronic obstructive pulmonary disease (COPD), cerebrovascular event history. Off-pump reduction aortoplasty with external wrapping was first described by Arsan⁽³⁾.

CASE REPORT

We have performed 75 ascending aorta aneurysm operations in the last 5 years. Of these, 10 cases included external wrapping. Between April 2007 and July 2009, 3 patients (4% of all cases) were on off-pump reduction aortoplasty and concomitant coronary artery bypass grafting (CABG). The first patient was a 75-year-old man who had a 50 mm ascending aorta, obesity (Body Mass Index: 31.14) and cerebrovascular event history. We preferred off-pump operation for early mobilization of the patient. The second patient was a 66-year-old heavy smoker who had COPD and 49 mm in diameter ascending aorta. His pulmonary function was poor (forced expiratory volume 1: 65% and O₂ saturation: 85% in air room under medication), so off-pump operation was chosen to avoid the adverse effect of cardiopulmonary bypass on

Correspondence

Adnan Yalçınkaya

E-mail: adnanyalcinkaya@gmail.com

Submitted: 09.08.2015

Accepted: 04.09.2015

© Copyright 2017 by Koşuyolu Heart Journal.
Available on-line at
www.kosuyoluheartjournal.com

lungs. The third patient was a 79-year-old heavy smoker who had 48 mm ascending aorta, COPD (forced expiratory volume 1: 68% and O₂ saturation: 87% in air room under medication) and obesity (body mass index: 32.59). The patients' preoperative and operative data are shown in Table 1.

After standard anesthesia, transesophageal echocardiography probe was placed to evaluate ascending aortic atherosclerotic plaque. Then median sternotomy was performed. Left internal mammarian artery and saphenous vein grafts were harvested.

Systemic heparin was administered at a dose of 2 mg/kg. All distal anastomoses were performed using a myocard stabilizer. Left internal mammarian artery was anastomosed to the left anterior descending artery initially. Then, the other distal anastomoses were performed. Proximal anastomotic site was placed close to sinotubular junction of the aorta.

Aorta was dissected from pulmonary artery and peripheral tissue gently. Then, aorta wrapped with longitudinally cut 30 mm Dacron graft on beating heart. Systolic arterial pressure was kept

Table 1. The patients preoperative and operative data are shown

Variable	Patient 1	Patient 2	Patient 3
Age/Sex	75/Male	66/Male	79/Male
Comorbit conditions	Obesity, CVE	Severe COPD	Severe COPD, obesity
Other risk factors	DM, HT	HT, HL	DM, HT, HL
Size of the aorta (mm)	50	49	48
LVEF %	43	48	50
Stenotic coronary artery	LAD (95%)	LAD (80%) RCA Prox (90%)	LAD (90%)
Coronary procedures (BH) (+ reduction aortoplasty)	LIMA-LAD	LIMA-LAD Ao-SVG-RCAM	LIMA-LAD
Total operation time (min)	120	145	140
Postoperative drainage (mL)	400	450	450
ICU stay/Intibation time (h)	15/7	17/8	14/9
Hospitalization (day)	5	6	6
Follow up time (months)	47	59	51
Aortic size at control (mm)(inner size)	27	26.5	26

Ao: Aorta, CVE: Cerebrovascular event, COPD: Chronic obstructive pulmonary disease, DM: Diabetes mellitus, HL: Hyperlipidemia, HT: Hypertension, ICU: Intensive care unit, LAD: Left anterior descending, LVEF: Left ventricle ejection fraction, LIMA: Left Internal mammary artery, OM: Obtuse margin branch of circumflex artery, RCA: Right coronary artery, RCAM: Right coronary artery acute margin branch, SVG: Saphenous vein graft.

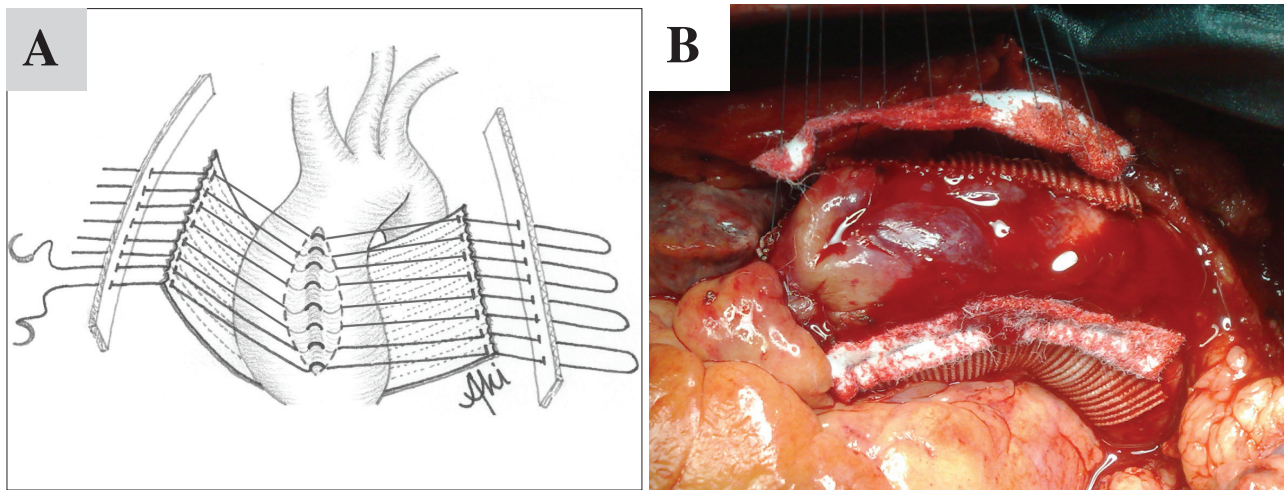


Figure 1. (A) Aorta wrapped with longitudinally cut 30-mm Dacron. Single 5 or 6 U-sutures were used to plicate the fusiform aneurysmatic segment of the aorta between the free sides of graft. Plicated segment of aorta must be diamond shape. **(B)** Intraoperative view of passed sutures.

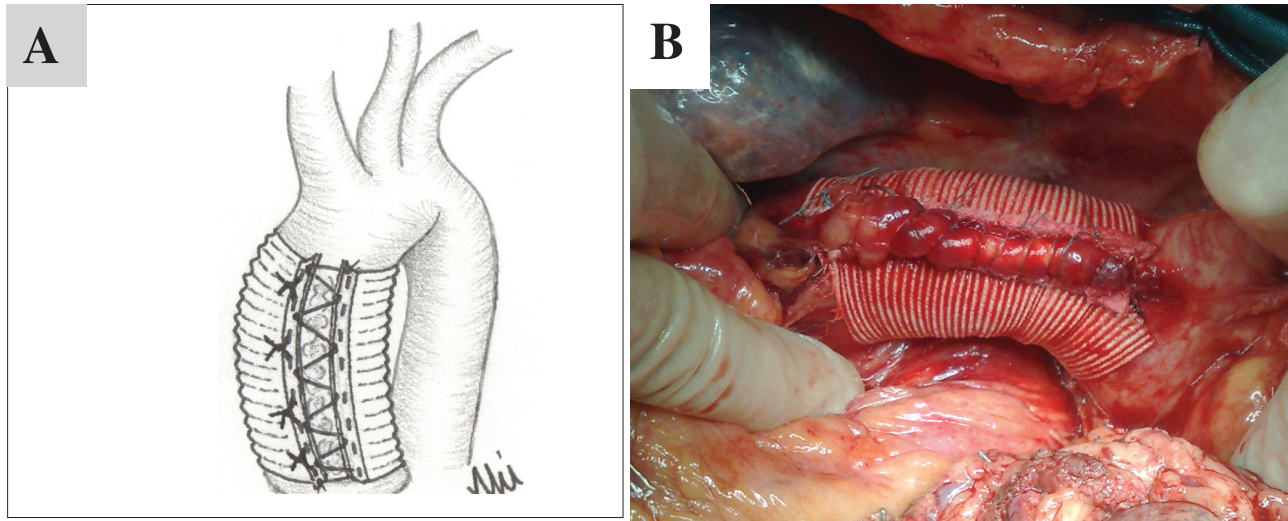


Figure 2. (A) Sutures tie at the end. (B) Intraoperative view of off-pump wrapped aorta.

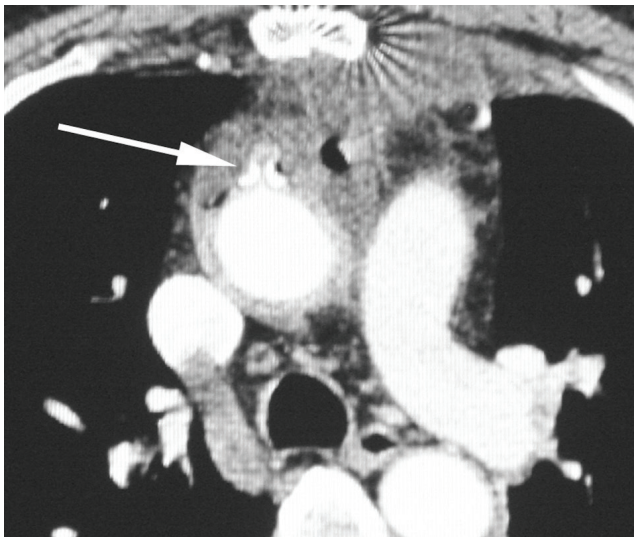


Figure 3. Postoperative control computerized tomography angiography. Arrow shows the suture line.

under 90 mmHg with controlled esmolol infusion. Single 5 or 6 U-sutures used to plicate the fusiform aneurysmatic segment of the aorta between the free sides of graft (Figure 1A,B). Systolic arterial pressure was dropped about 40 mmHg via inferior vena cava occlusion by fingers to tie sutures (Figure 2A,B). After hemodynamic stabilization, operation was terminated. The external tube graft did not retract the proximal anastomosis due to the exclusion of the proximal anastomotic site from the wrapping side. All patients had an uneventful recovery.

The length of stay in the intensive care unit and the hospital were shorter than expected (Table 1). Control computerized tomography angiography showed that ascending aorta of the patients were in normal limits (26-27 mm in diameter) and all coronary grafts were patent (Figure 3).

DISCUSSION

Indication for concomitant operation includes CABG patients who have ascending aorta aneurysm of greater than 4.5 cm. In case of ascending aortic aneurysm, the general consensus tends toward performing ascending aortic replacement rather than aortoplasty with or without external wrapping. But, patients requiring concomitant CABG may have a lesser chance of survival than with isolated surgery in the next years due to adverse effects of long extracorporeal circulation time or emergent surgery, as well as independent risk factors such as cardiac or non-cardiac diseases⁽⁴⁾. Off-pump cardiac surgery may be the best surgical alternative approach to avoid these adverse effects. Off-pump reduction aortoplasty with external wrapping, described by Arsan, can be a solution for high-risk patients⁽³⁾.

Whether on-pump or off-pump is utilized, aortoplasty with external wrapping includes some complications as its own; for example, embolic stroke due to atherosclerotic plaque rupture. To reduce the risk of embolism, aortic wall must be evaluated with transesophageal echocardiography or computerized tomography before the aortoplasty. The other complications are erosion and dislocation. Bauer et al. reported a dislocated wrap causing erosion of the ascending aorta after 4 years⁽⁵⁾. Erosion can be appear due to necrosis since the aortic wall is under the pressure by wrap externally, and blood flow internally. Neri et al. reported on 2 patients developed false ascending aorta aneurysm after 7 and 11 years⁽⁶⁾. Both these reports are on-pump wrapping aortoplasty. Akgun et al. reported that 2 of 12 patients had developed aortic dissection and 1 of the 12 patients had developed aortic root aneurysm after off-pump wrapping aortoplasty⁽⁷⁾. We predict that these complications are results of progressive aortic disease. Although these complications are adverse effects of wrapping aortoplasty, wrapping aortoplasty and concomitant CABG may still sometimes be required to be performed along with off-pump

in selective patients to avoid from available risks. We performed both off-pump surgery and wrapping aortoplasty concomitant CABG on 3 high-risk patients. Thus, we benefited from the advantageous of off-pump surgery. Another reason may be the appropriate diameter of ascending aorta (between 4.5 cm and 6 cm) and the greater strength of aortic wall layers than other large-scale diameters of the ascending aorta.

Calafiore et al. and Ascione et al. reported the advantages of off-pump CABG^(8,9). In these studies, they showed that off-pump CABG surgery decreased ventilation time, intensive care and length of hospital stay, and early major events. In addition, off-pump CABG contributed to early mobilization and patient comfort. Guler et al. reported off-pump bypass surgical procedures are more advantageous than on-pump methods for patients with COPD respect pulmonary functions⁽¹⁰⁾. Although, our patients had high risks, off-pump surgery contributed to decreased ventilation time, intensive care unit, and length of hospital stay than expected.

As a result, patients' postoperative courses were uneventful and mid-term results were satisfactory. One of our patients is in their fourth year without facing any problem.

Consequently, we believe that wrapping aortoplasty concomitant CABG should be performed with off-pump surgery to salvage troublesome situations on selected patients who are elderly and cannot tolerate cardiopulmonary bypass and aortic cross-clamp because of severe cardiac and non-cardiac diseases.

REFERENCES

1. Egloff L, Rothlin M, Kugelmeier J, Senning A, Turina M. The ascending aorticaneurysm: replacement or repair? *Ann Thorac Surg* 1982;34:117-24.
2. Arsan S, Akgun S, Kurtoglu N, Yildirim T, Tekinsoy B. Reduction aortoplasty and external wrapping for moderately sized tubular ascending aortic aneurysm with concomitant operations. *Ann Thorac Surg* 2004;78:858-61.
3. Arsan S. Off-pump reduction aortoplasty and concomitant coronary artery bypass grafting. *Ann Thorac Surg* 2004;78:316-9.
4. Narayan P, Rogers CA, Caputo M, Angelini GD, Bryan AJ. Influence of concomitant coronary artery bypass graft on outcome of surgery of the ascending aorta/arch. *Heart* 2007;93:232-7.
5. Bauer M, Grauhan O, Hetzer R. Dislocated wrap after previous reduction aortoplasty causes erosion of the ascending aorta. *Ann Thorac Surg* 2003;75:583-4.
6. Neri E, Massetti M, Tanganelli R, Capannini G, Carone E, Tripodi A, et al. Is it only a mechanical matter? Histologic modifications of the aorta underlying external banding. *J Thorac Cardiovasc Surg* 1999;118:1116-8.
7. Akgun S, Atalan N, Fazlioğullari O, Kunt AT, Basaran C, Arsan S. Aortic root aneurysm after off-pump reduction aortoplasty. *Ann Thorac Surg* 2010;90:e69-70.
8. Calafiore AM, Di Mauro M, Contini M, Di Giammarco G, Pano M, Vitolla G, et al. Myocardial revascularization with and without cardiopulmonary bypass in multivessel disease: impact of the strategy on early outcome. *Ann Thorac Surg* 2001;72:456-62.
9. Ascione R, Lloyd CT, Underwood MJ, Lotto AA, Pitsis AA, Angelini GD. Economic outcome of off-pump coronary artery bypass surgery: a prospective randomized study. *Ann Thorac Surg* 1999;68:2237-42.
10. Güler M, Kirali K, Toker ME, Bozbuğa N, Omeroğlu SN, Akinci E, et al. Different CABG methods in patients with chronic obstructive pulmonary disease. *Ann Thorac Surg* 2001;71:152-7.