

■ Case Report

A case report of primary appendiceal cancer mimicking ovarian cancer

Over kanserini taklit eden primer appendisiyal kanseri olgu sunumu

Ümit GÖRKEM^{1a}, Tayfun GÜNGÖR¹, Tayfun ŞAHİNER², Yılmaz BAŞ³, Cihan TOĞRUL¹

¹Hitit University, Faculty of Medicine, Department of Obstetrics and Gynecology Çorum,

²Hitit University, Faculty of Medicine, Department of General Surgery, Çorum,

³Hitit University Hospital, Faculty of Medicine, Department of Pathology, Çorum, TURKEY

ABSTRACT

The case reported here describes primary appendiceal adenocarcinoma(AACa) mimicking manifestations of ovarian malignancies. A 55-year-old woman with clinical findings of ovarian cancer underwent laparotomy in which an appendiceal tumor was encountered. Total abdominal hysterectomy, bilateral salpingo-oophorectomy, appendectomy, right hemicolectomy and omentectomy were performed. Final histopathological result demonstrated mucinous adenocarcinoma with signet ring epithelial cells. Therefore, AACa should be kept in mind by gynecological surgeons for differential diagnosis of ovarian malignancies, since therapeutic approaches differ from each other

Key Words: Primary appendiceal cancer, appendiceal adenocarcinoma, ovarian cancer

ÖZ

Bu yazıda ovaryan malignansi bulgularını taklit eden bir primer appendisiyal adenokarsinoma olgusu sunulmaktadır. Over kanseri klinik bulgularına sahip 55 yaşındaki bir kadın hastaya yapılan laparatomide appendisiyal tümör ile karşılaşıldı. Total abdominal histerektomi, bilateral salpingo-ooferektomi, appendektomi, sağ hemikolektomi ve omentektomi uygulandı. Histopatolojik sonuç taşlı yüzük epitelyal hücreli musinöz adenokarsinom olarak rapor edildi. Appendisiyal adenokarsinom, farklı terapötik yaklaşım içermesi nedeniyle ovaryan malignansilerin ayırıcı tanısında akılda tutulmalıdır.

Anahtar Kelimeler: Primer appendisiyal kanser, appendisiyal adenokarsinom, over kanseri

Corresponding Author^a: Umit GÖRKEM, MD. Hitit University, Çorum Education and Research Hospital, Department of Obstetrics and Gynecology, Çorum, TURKEY

Phone: 0090-533-3479942 e-mail: drumitgorkem@hotmail.com

doi: 10.18663/tjcl.98904

Bu olgu sunumu, 11-15 Mayıs.2015 tarihleri arasındaki Antalya'da gerçekleşen 13. Ulusal Jinekoloji ve Obstetrik (TJOD) Kongresinde poster olarak sunulmuştur.

Introduction

Primary appendiceal tumors are rare tumors which are mostly carcinoids. Primary appendiceal adenocarcinoma (AACa) represents nearly 0,5% of all cancers of the gastrointestinal tract and 5% of primary appendiceal neoplasms. The clinical manifestations of primary AACa include a palpable mass or acute appendicitis and are mostly suspicious for clinicians [1-3]. Hence, these tumors are often discovered incidentally at the time of surgery. Appendiceal cancers commonly spread to neighboring organs such as ovaries. Furthermore, the differential diagnosis of ovarian cancers also includes appendiceal cancers in which preoperative recognition with abdominal ultrasonography or computerized tomography is often misleading [3]. Herein, we represent a case of primary AACa which mimics an ovarian cancer at advanced stage.

Case Report

A 55-year-old female, gravida 4, para 3, was referred to the Hitit University Hospital with the complaints of abdominal pain and distension that had been persisting for a period of four months. Abdominal examination revealed a protuberant, tense and diffusely tender abdomen. Hepatosplenomegaly was detected by palpation. Laboratory results including Ca125 levels were in the normal range. On abdominopelvic ultrasonography, a diffuse ascites and a heterogeneous mass measuring 79 x 40 mm in diameter were determined. Rectosigmoidoscopy revealed normal findings. On contrast-enhanced computerized tomography, a diffuse ascites and a heterogeneous, hypodense mass, measuring 61x53 mm in diameter and possessing calcifications in the outer layers were reported. The right ovary could not be detected as a separate organ (Fig. 1).

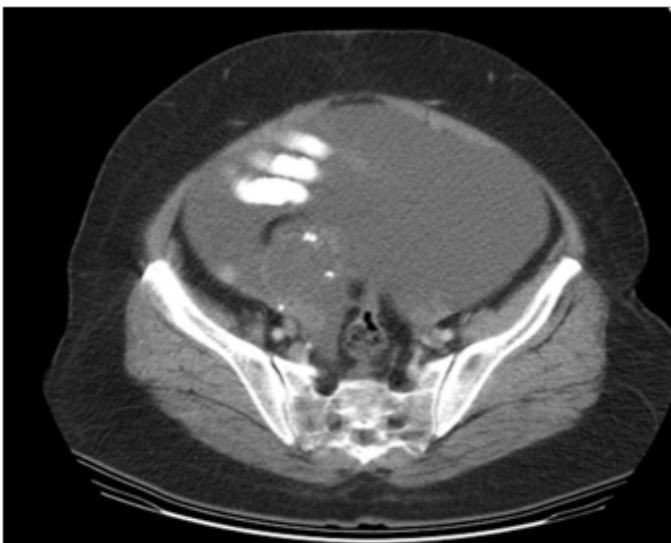


Figure 1: The contrast-enhanced computerized tomography imaging of the abdomen.

Based on the clinical presentation, physical findings and radiographic results, a clinical diagnosis of ovarian malignancy was presumed. Laparotomy was performed, which revealed 2 liters of ascites, normal ovaries bilaterally, and an appendiceal tumor measuring 80 x 70 mm. A sample of the ascites fluid was sent to the laboratory for cytological examination. Miliary metastatic foci were found on the surfaces of the parietal peritoneum of the anterior abdominal wall, omentum, uterus and both fallopian tubes. Total abdominal hysterectomy, bilateral salpingo-oophorectomy, appendectomy, right hemicolectomy and omentectomy were performed. The frozen section of the specimen demonstrated mucinous adenocarcinoma with signet ring epithelial cells. The cytological result was reported as malignant. After an uneventful postoperative 10-day course, she was discharged from the hospital.

The final histopathological result revealed diffuse atypical signet ring-like epithelial cells in both adnexa, omentum, peritoneum of the diaphragm and the Douglas pouch, containing a large amount of mucin which pushed the nuclei to the cell periphery (Fig. 2). Immunohistologic examination demonstrated synaptophysin-negative, CK 20-positive, CK 7-negative, WT1-negative, CDX2-positive stained cells.

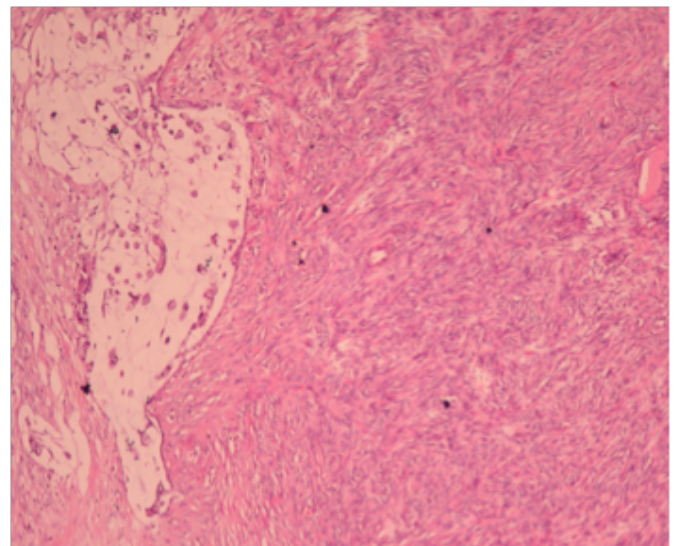


Figure 2: The histopathology demonstrating diffuse atypical signet ring-like epithelial cells.

Discussion

Primary AACAs are rare cases that are seldom reported in the literature. Since AACa is rarely diagnosed preoperatively, most gynecological surgeons do not assume the site of tumor as the appendix. The clinical manifestations of these two disorders usually resemble that of ovarian carcinoma. Appendiceal malignancies are detected in only 0,9 - 1.4% of all appendec-

tomy specimens [4]. The AACAs are composed of mucinous, colorectal, mixed mucinous and signet ring, and signet ring type. The presence of signet ring cell is a poor prognostic sign [5]. Ovarian metastases are seen in 16,7% to 37% of AACAs [4]. Ovarian metastases from mucinous AACAs mimic primary ovarian mucinous carcinomas.

On the basis of a conventional pathological evaluation, it is a problem to establish whether the carcinoma has originated from the ovary or the appendix. Therefore, we used immunohistologic staining in the specimens. However, immunohistologic staining has a disadvantage in frozen section histological evaluation, since it is time consuming and therefore, cannot be used.

The differential diagnosis is clinically significant since the therapeutic approach yields different results in ovarian and appendiceal cancers. An optimal surgical debulking is the main preference of therapy in ovarian cancers [6,7], whereas radical tumor debulking remains controversial in appendiceal cancers [4,5,8-10].

In conclusion, although uncommon, primary AACa should be kept in mind by gynecological surgeons in the differential diagnosis of ovarian malignancies, because the therapeutic options differ from each other. The appendix should be meticulously examined during the surgical exploration for ovarian masses and prophylactic appendectomy should be considered as a part of ovarian cancer surgery. Primary appendiceal cancer may be the origin of malignancy.

Declaration of conflicting interests

The authors declared no conflicts of interest with respect to the authorship and/or publication of this article.

Funding

The authors received no financial support for the research and/or authorship of this article.

References

1. Conte CC, Petrelli NJ, Stulc J, Herrera L, Mittelman A. Adenocarcinoma of appendix. *Surg Gynecol Obstet* 1988; 166: 451-3.
2. Ozakyol AH, Saricam T, Kabukcuoglu S, Caga T, Erenoglu E. Primary appendiceal adenocarcinoma. *Am J Clin Oncol* 1999; 22: 458-9.
3. Nitecki SS, Wolff BG, Schlinkert R, Sarr MG. The natural history of surgically treated primary adenocarcinoma of the appendix. *Ann Surg* 1994; 219: 51-7.
4. Jun S, Shinsuke K, Jon K, Hiroshi U, Tetsuro M, Hirokazu N. Signet ring cell carcinoma of the appendix manifesting as colonic obstruction and ovarian tumors: report of a case. *Surg Today*. 2009; 39: 235-40.
5. Valentina RB, Federico C, Antonio DP. Peritoneal seeding from appendiceal carcinoma: A case report and review of the literature. *World J Gastrointest Surg* 2010; 2: 265-69.
6. Hoskins WJ. Epithelial ovarian carcinoma. principles of primary surgery. *Gynecol Oncol* 1994; 55: S91-6.
7. Hoskins WJ, Bundy BN, Thigpen JT, Omura GA. The influence of cytoreductive surgery on recurrence-free interval and survival in small-volume stage III epithelial ovarian cancer: a gynecologic oncologic group study. *Gynecol Oncol* 1992; 47: 159-66.
8. Carl R, Louay H, Vladimir G, Ghulamullah S, Muhammad WS. Cancers of the appendix: review of literature. *ISRN Oncology* 2011. doi:10.5402/2011/728579.
9. Samer ES, Ulrich S, Hans RT, Andreas H, Karsten M. Primary signet ring cell mucinous ovarian carcinoma: a case report and literature review. *Case Rep Oncol*. 2010; 3: 451-57.
10. Gehrig PA, Boggess JE, Ollila DW, Groben PA, Van LL. Appendix cancer mimicking ovarian cancer. *Int J Gynecol Cancer* 2002; 12: 768-72.