

# Migration of an forgotten intrauterine device into the urinary bladder

Levent Sağnak (\*), Hamit Ersoy (\*\*), Fuat Aksun (\*), Uğur Özok (\*), Nihat Karakoyunlu (\*), Hikmet Topaloğlu (\*),

## ABSTRACT

Spontaneous migration of the intrauterine devices(IUD) into the bladder is a rare complication. We report and describe the clinical outcome and management of one such case of intravesical IUD. The diagnosis was confirmed after cystoscopic visualization. Endoscopic examination allowed removal of the IUD.

**Key words:** Intrauterine device; migration; urinary bladder

## ÖZET

### Mesaneyeye migrate unutulmuş rahimiçi araç

Rahimiçi araçların(RIA) mesaneyeye migrasyonu oldukça seyrek görülen bir komplikasyondur. Bu olgu sunumumuzda böyle bir intravezikal RIA vakasının klinik belirtilerini ve tedavi yaklaşımımızı sunmaktayız. Kesin tanı sistoskopik olarak konmuştur. RIA'nın çıkarılmasında endoskopik yaklaşım tercih edilmiştir.

**Anahtar kelimeler:** Rahimiçi araç; migrasyon; mesane

## Introduction

Intrauterine contraceptive devices(IUD) have been in use for more than 30 years<sup>[1]</sup> and most widely used as modern contraceptive method in Turkey for the last 20 years.<sup>[2]</sup> More than 100 million women worldwide have been using the IUD. Although perforation of the uterus by an intrauterine device is not uncommon, intravesical migration with secondary stone formation is a rare complication.<sup>[3]</sup> This report describes a case of intravesical IUD penetration requiring endoscopic surgical intervention.

## The Case

A 33-year-old patient (gravida 3, parity 3) was admitted to our clinic with complaints of pelvic pain and macroscopic hematuria. Urinalysis and all other laboratory findings including a complete blood count and blood biochemistry profile were within normal levels. There were no data to support tendency of urolithiasis and urinary infection. The physical examination revealed no abnormalities. On her past medical therapy there was an IUD insertion 6 years ago. As noted from the patient's medical history, an IUD had been inserted in 2004, at the postpartum period of her 2<sup>nd</sup> child's birth (it's a normal vaginal childbirth) at a family planning unit and she had no specific complaint after the procedure. Unexpectedly, she had become pregnant 1 year later and had given again a vaginal birth without complications. The IUD had not been recovered and it was assumed that it had fallen out. She had been treated empirically for urinary tract infection several times by different general practitioners without proper investigation by urinary tract imaging and cystoscopy. When she applied to our clinic, it was the first time she was seen by a urologist.

\* S.B.Dışkapı Yıldırım Beyazıt Eğitim ve Araştırma Hastanesi Üroloji Kliniği, Ankara, Türkiye

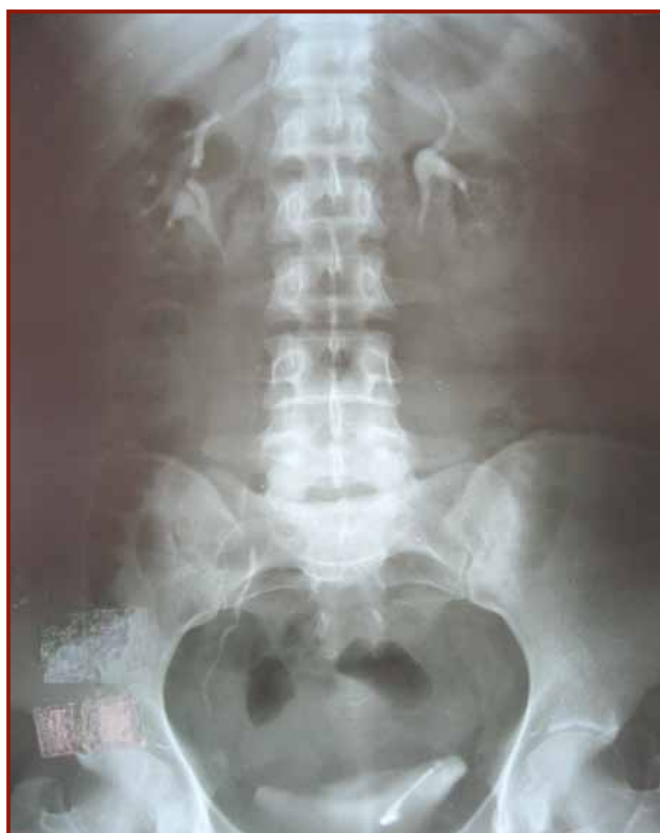\*\*Hitit University, Department of Urology, Çorum, Türkiye

**Reprint request:** Levent Sağnak, S.B.Dışkapı Yıldırım Beyazıt Eğitim ve Araştırma Hastanesi Üroloji Kliniği, Ankara, Türkiye

**E-mail:** leventsagnak@gmail.com

**Date submitted:** October 05, 2011 **Date accepted:** January 11, 2012 **Online publication date:** September 26, 2013

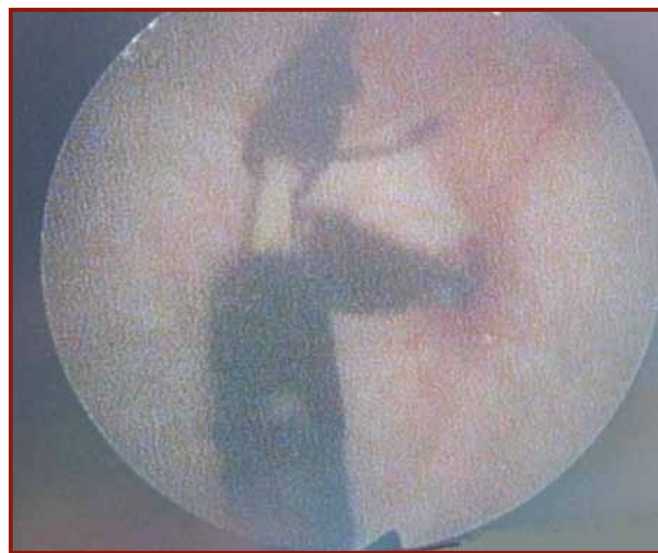
The vaginal examination revealed that the IUD was dislocated. Pelvic ultrasonography revealed hyperechogenicity in the bladder wall, which might be consistent with IUD. Intrauterine device was detected in the pelvis via direct pelvic radiography examinations. No pathological findings were established in the abdomen ultrasonography. Intravenous pyelography showed us that the IUD was overlapped over the urinary bladder (Figure 1). Cystoscopic examination under local anesthesia, revealed that the IUD was penetrating the posterior wall of the bladder and was fixed to the bladder wall (Figure 2), not lying free in the bladder with calculus formation surrounding it's body partially. A second cystoscopy was performed under general anesthesia, but the tail of IUD cannot grasped by standard forceps. Then the application was repeated by using nephroscopy shaft and nephrostomy forceps and the IUD was easily removed as a whole unit by pulling it through the perforation site and by the aim of gently taken out through the cystoscope we divided the IUD into two pieces intravesically(Figure 3). A Foley catheter was left in bladder for 5 days. The patient was discharged 3 days after the IUD removal without complication.



**Figure 1.** IUD overlapping on to the urinary bladder in IVP

## Discussion

There are about 110 case reports published about the migration of IUDs outside the uterine cavity and in about 80 of these cases, the IUDs were located in the bladder with or without they being calcified.<sup>[1]</sup> The overall reported incidence of intrauterine device perforation is about 0.87 per 1000 insertions.<sup>[4]</sup> This includes the pelvis, peritoneal cavity and adjacent organs. Due to the asymptomatic nature of the perforation, the true incidence of the uterus perforation by an IUD is most likely higher than reported.<sup>[5]</sup> The exact mechanism that causes uterine perforation and migration of the IUD is not entirely known. The most important factor related with this complication is probably the operator experience in IUD application. There are also many factors that affect uterine perforation, such as the uterine size, position, timing of the insertion, congenital uterine anomalies and former operations.<sup>[6]</sup> Previous Cesarean section was a risk factor of uterine perforation by IUD.



**Figure 2.** Cystoscopic evaluation of IUD on bladder wall



**Figure 3.** Removed IUD (divided)

At the postpartum period of her 2<sup>nd</sup> child's birth our patient had been inserted an IUD at a family planning unit. It may be argued that (as a hypothesis) a mistaken urethral insertion of IUD might be done, as for an uterine application, but as there was no early symptoms like hematuria, pain during micturia, severe and hardly curable urinary infections etc. we canceled this hypothesis.

As she learned she was pregnant for her 3<sup>rd</sup> child unexpectedly, one year after the IUD insertion, she went to a State Hospital for an obstetrical examination. At initial control, as an answer, they said that the IUD had fallen out (this comment might belong to a nurse-the patient can't remember it correctly) and then our patient did not ask any question on this subject again. She made her routine obstetrical follow-up controls in the same hospital but according to her answers she had never been applied an usg imaging. We think that, as she accepted the evidence of fallen IUD and stopped mentioning about it, during usg controls (if done) the obstetrician didn't come to mind to search a possible migration and we must not forget that she was also asymptomatic. We also suppose, as she was pregnant no one thought to take a plain radiography. In such huge public hospitals like, the pregnant's routine controls was made in an automatic manner and no one had a special obstetrician as the doctors were differ in every visit, so no one might remember and search a forgotten IUD after birth.

However, the uterine atrophy and thinning of the uterine walls due to hypoestrogenism, involution of uterus, strong uterine contractions and soft consistency of the uterus can increase the risk of perforation.<sup>[7]</sup> It was, therefore, suggested to postpone the IUD insertion until 3 months after delivery to be safe.<sup>[5,7]</sup> Spontaneous uterine contractions, bowel peristalsis and bladder contractions are other physiological mechanisms that may cause spontaneous migration of the IUD.<sup>[8]</sup> Uterine perforation can occur at the time of the insertion or at any other time after the insertion. The interval between the insertion and removal of the device ranged from 6 months to 16 years.<sup>[9]</sup> In our case the interval amounted to 6 years.

Patients may present with irritative voiding symptoms, dysuria, recurrent urinary tract infections, hematuria, incontinence and suprapubic abdominal pain.<sup>[4,5,9]</sup> These patients may have multiple time antibiotic therapies, if they are not evaluated

appropriately. The duration of the symptoms before diagnosis ranged from 6 months to 5 years.<sup>[10]</sup> More than half of the patients were diagnosed before becoming symptomatic.<sup>[10]</sup>

If the IUD strings can not be observed during the vaginal examination and is not detected in the endometrial cavity via ultrasonography, IUD dislocation should be considered. The patients must be evaluated with pelvic radiography and in this image, when lost IUD is detected, calculus formation must be carefully researched. If calculus formation is detected in radiographic image, bladder perforation and the intravesical migration of IUD must be considered. It should be remembered that calculus formation does not occur in all intravesical IUDs, so the absence of calculus formation around IUD does not eliminate the suspicion of intravesical IUD. This may be related to the time elapsed since penetration of the IUD into the urinary bladder or the nature of the IUD.<sup>[11]</sup> Penetration of the device only in the bladder wall is evidently not associated with calculus formation.<sup>[6]</sup> Advanced imaging methods and cystoscopic evaluations are needed for the case which has no stone formation round the IUD.<sup>[9]</sup>

The IUD that dislocates into the bladder should be removed due to the potential complications and symptoms it causes. Also the current accepted management is removal of the device from the abdominal cavity in order to prevent further morbidity.<sup>[1]</sup> Cystoscopy or suprapubic cystostomy can be used for treatment.<sup>[12]</sup>

In such cases, patients generally develop adhesions due to recurrent sepsis and urinary tract infection. Genitourinary fistulas may be seen. So in order to avoid genitourinary fistulas, minimally invasive endourological management should be preferred.<sup>[1]</sup> Endoscopic retrieval of migrant IUD is the preferred option. In the cases with the IUDs found completely inside the bladder, cystoscopic extraction of the device and the stones were successful without complications, the tiny hole created between bladder and uterine wall will close after few days of bladder drainage by a Foley catheter. On the other hand, in the case with partial penetration of the bladder wall, open surgery was utilized to retrieve the device and repair the defect.<sup>[13]</sup> There is a real need to optimize surgical treatment of displaced IUDs due to increase in morbidity from extensive open surgical explorations. Also patient expectations necessitate treatment by the least invasive procedure that is, endoscopically.<sup>[1]</sup>

After the treatment, genitourinary fistulas might be seen. The presenting complaints of genitourinary fistulas are permanent, total and isolated urinary incontinence, partial urinary incontinence associated with menstrual hematuria, vesical menstrual bleeding associated with oligomenorrhoea and menouria.<sup>[14]</sup> But our patient had no complaints at the end of the 14<sup>th</sup> month follow-up.

The present case demonstrates that uterine perforation caused by IUDs and migration into the urinary bladder can go unnoticed. Chronic pelvic pain, irritative voiding symptoms and haematuria with a history of unretrieved IUD must be carefully researched for possible intravesical migration (if there were acute symptoms after the application, an urethral insertion of IUD must be initially considered, as it was a logical hypothesis). The insertion of IUDs by trained medical personel and the adoption of careful insertion techniques would go a long way to preventing this complication.

## References

1. Yensel U, Bezircioglu I, Yavuzcan A, Baloglu A, Cetinkaya B. Migration of an intrauterine device into the bladder: a rare case. *Arch Gynecol Obstet* 2009;279:739-742
2. Contraception, abortion and maternal health services in Turkey: Results of further analysis of the 1998 Turkish demographic and health survey. Ed.Akin A, Hacettepe University Medical Faculty Department of Public Health, Turkish Family Health and Planning Foundation, UNFPA; 2002
3. Demirci D, Ekmekçioğlu O, Demirtaş A, Gülmez İ. Big bladder stones around an intravesical migrated intrauterine device. *Int Urol Nephrol* 2003;35:495-496
4. Markovitch O, Klein Z, Gidoni Y, Holzinger M, Beyht Y. Extrauterine mislocated IUD: is surgical removal mandatory? *Contraception* 2002;66:105-108
5. Tosun M, Celik H, Yavuz E, Çetinkaya MB. Intravesical migration of an intrauterine device detected in a pregnant woman. *Can Urol Assoc J* 2010;4:E141-143
6. Tuncay YA, Tuncay E, Güzin K, Öztürk D, Omurcan C, Yücel N. Transuterine migration as a complication of intrauterine contraceptive devices: six case reports. *Eur J Contracept Reprod Health Care* 2004;9:194-200
7. Caliskan E, Ozturk N, Dilbaz BO, Dilbaz S. Analysis of risk factors associated with uterine perforation by intrauterine devices. *Eur J Contracept Reprod Health Care* 2003;8:150-155
8. Eke N, Okpani AO. Extrauterine translocated contraceptive device: a presentation of five cases and revisit of the enigmatic issues of iatrogenic perforation and migration. *Afr J Reprod Health* 2003;7:117-23
9. Hoşcan MB, Koşar A, Gümüştas Ü, Güney M. Intravesical migration of intrauterine device resulting in pregnancy. *Int J Urol* 2006;13:301-302
10. Özgür A, Şişmanoğlu A, Yazıcı C, Coşar E, Tezen D. Intravesical stone formation on intrauterine contraceptive device. *Int Urol Nephrol* 2004;36:345-348.
11. Dede SF, Dilbaz B, Sahin D, Dilbaz S. Vesical calculus formation around a migrated copper-T 380-A. *Eur J Contracept Reprod Health Care* 2006;11:50-52
12. Zakin D, Stern WZ, Rosenblatt R. Complete and partial uterine perforation and embedding following insertion of intrauterine devices. II. Diagnostic methods, prevention, and management. *Obstet Gynecol Surv* 1981;36:401-417
13. El-Hefnawy AS, El-Nahas AR, Osman Y, Bazeed MA. Urinary complications of migrated intrauterine contraceptive device. *Int Urogynecol J Pelvic Floor Dysfunct* 2008;19:241-245
14. Benchekroun A, Lachkar A, Soumana A, Farih MH, Belahnech Z, Marzouk M et al. Vesico-uterine fistulas. Report of 30 cases. *Ann Urol(Paris)* 1999;33:75-79.